

Livebirth after orthotopic transplantation of cryopreserved ovarian tissue



J Donnez, M M Dolmans, D Demylle, P Jadoul, C Pirard, J Squifflet, B Martinez-Madrid, A Van Langendonck

Summary

Background The lifesaving treatment endured by cancer patients leads, in many women, to early menopause and subsequent infertility. In clinical situations for which chemotherapy needs to be started, ovarian tissue cryopreservation looks to be a promising option to restore fertility. In 1997, biopsy samples of ovarian cortex were taken from a woman with stage IV Hodgkin's lymphoma and cryopreserved before chemotherapy was initiated. After her cancer treatment, the patient had premature ovarian failure.

Methods In 2003, after freeze-thawing, orthotopic autotransplantation of ovarian cortical tissue was done by laparoscopy.

Findings 5 months after reimplantation, basal body temperature, menstrual cycles, vaginal ultrasonography, and hormone concentrations indicated recovery of regular ovulatory cycles. Laparoscopy at 5 months confirmed the ultrasonographic data and showed the presence of a follicle at the site of reimplantation, clearly situated outside the ovaries, both of which appeared atrophic. From 5 to 9 months, the patient had menstrual bleeding and development of a follicle or corpus luteum with every cycle. 11 months after reimplantation, human chorionic gonadotrophin concentrations and vaginal echography confirmed a viable intrauterine pregnancy, which has resulted in a livebirth.

Interpretation We have described a livebirth after orthotopic autotransplantation of cryopreserved ovarian tissue. Our findings suggest that cryopreservation of ovarian tissue should be offered to all young women diagnosed with cancer.

Introduction

Treatment of childhood malignant disease is becoming increasingly effective. Aggressive chemotherapy and radiotherapy, and bone-marrow transplantation, can cure more than 90% of girls and young women affected by such disorders. However, the ovaries are very sensitive to cytotoxic treatment, especially to alkylating agents and ionising radiation, generally resulting in loss of both endocrine and reproductive function.¹ Moreover, uterine irradiation at a young age reduces adult uterine volume.²

By 2010, about one in 250 people in the adult population will be childhood cancer survivors.³ Several potential options are available to preserve fertility in patients facing premature ovarian failure, including immature and mature oocyte cryopreservation, and embryo cryopreservation.^{4,5} For patients who need immediate chemotherapy cryopreservation of ovarian tissue is a possible alternative.^{4,6,7} The aim of this strategy is to reimplant ovarian tissue into the pelvic cavity (orthotopic site) or a heterotopic site like the forearm once treatment is completed and the patient is disease-free.^{4,8–12}

Oktay and colleagues have reported laparoscopic transplantation of frozen-thawed ovarian tissue to the pelvic side wall,⁸ forearm,⁹ and beneath the skin of the abdomen. A four-cell embryo was obtained from 20 oocytes retrieved from tissue transplanted to the abdomen, but no pregnancy happened after transfer.¹³ Radford and colleagues¹² reported a patient with a history of Hodgkin's disease treated by chemotherapy,

in whom ovarian tissue had been biopsied and cryopreserved 4 years after chemotherapy and later reimplanted. In this case, histological section of ovarian cortical tissue revealed only a few primordial follicles because of the previous chemotherapy. After reimplantation, the patient had only one menstrual period. In 2004, a livebirth after a fresh ovarian tissue transplant in a primate was reported.¹⁴

In 1995, the Catholic University of Louvain ethics committee approved a protocol to assess the safety and efficacy of cryopreservation of ovarian tissue in women treated with high doses of chemotherapy, which could induce ovarian failure. So far, 146 patients have undergone cryopreservation of ovarian tissue in our department before starting chemotherapy and two patients have undergone reimplantation (one in August, 2004).

Here, we describe the outcome of orthotopic autotransplantation of cryopreserved ovarian tissue in a patient from whom tissue was obtained and frozen before chemotherapy was initiated for Hodgkin's lymphoma.

Methods

Patient

In 1997, a 25-year-old woman presented with clinical stage IV Hodgkin's lymphoma. Ovarian tissue cryopreservation was undertaken before chemotherapy. We obtained written informed consent. By laparoscopy, we took five biopsy samples—about 12–15 mm long and 5 mm wide—from the left ovary. Removal of the whole ovary was not an option because one can never

Published online
September 24, 2004
<http://image.thelancet.com/extras/04art9230web.pdf>

Gynaecology Research Unit, Université Catholique de Louvain, Brussels, Belgium (M M Dolmans MD, D Demylle PhD, C Pirard MD, B Martinez-Madrid PhD, A Van Langendonck PhD); and Department of Gynaecology, Cliniques Universitaires St Luc, Université Catholique de Louvain, Avenue Hippocrate 10, B-1200 Brussels, Belgium (Prof J Donnez MD, P Jadoul MD, J Squifflet MD)

Correspondence to:
Prof Jacques Donnez
donnez@gyne.ucl.ac.be

completely exclude recovery of ovarian function after chemotherapy. Indeed, premature ovarian failure after chemotherapy is dependent on age, drug used, and dose given, and does not happen in all cases.

After laparoscopy, the patient received MOPP/ABV hybrid chemotherapy (chloroethamine, vincristine, procarbazine, prednisone, doxorubicin, bleomycin, vinblastine) from August, 1997, to February, 1998, followed by radiotherapy (38 Gy).

The patient became amenorrhoeic shortly after initiation of chemotherapy. After chemotherapy and radiotherapy, concentrations of follicle-stimulating hormone (FSH) were 91.1 mIU/mL, luteinising hormone (LH) 85 mIU/mL, and oestradiol 17 pg/mL, confirming castration. This ovarian failure profile was confirmed 3 months later. Hormone replacement therapy (HRT) was started in June, 1998, and then stopped in January, 2001, because the patient wanted to become pregnant. A thorough evaluation by oncologists showed that she was disease-free.

After cessation of HRT, concentrations of FSH, LH, and 17 β -oestradiol returned to levels consistent with ovarian failure. From January, 2001, to December, 2002, the patient had only one ovulatory cycle shown by a progesterone concentration of 10 ng/mL, and presence of a corpus luteum on the left ovary, diagnosed by vaginal echography. The decision to reimplant the cryopreserved tissue was therefore taken.

Procedures

Freezing of ovarian tissue was undertaken according to the protocol described by Gosden and colleagues.⁶ We immediately transferred biopsy samples to the laboratory in Leibovitz L-15 medium supplemented with Glutamax (GIBCO, Paisley, UK); at the laboratory the remaining stromal tissue was gently removed. We cut four biopsy samples of cortex into 70 small cubes of 2×2 mm, and one strip of 12×4 mm was left whole. These fragments of ovarian tissue were suspended in the cryoprotective medium. We placed all fragments into precooled 2 mL cryogenic vials (Simport, Quebec, Canada) filled with Leibovitz medium supplemented with 4 mg/mL of human serum albumin (Red Cross, Brussels, Belgium) and 1.5 mmol/L DMSO (Sigma, St Louis, MO, USA). The cryotubes were cooled in a programmable freezer (Kryo 10, Series III; Planer, Sunbury-on-Thames, UK) with the following programme: (1) cooled from 0°C to -8°C at -2°C/min; (2) seeded manually by touching the cryotubes with forceps prechilled in liquid nitrogen; (3) cooled to -40°C at -0.3°C/min; (4) cooled to -150°C at -30°C/min, and (5) transferred to liquid nitrogen (-196°C) immediately for storage.

We did the first laparoscopy 7 days before reimplantation to create a peritoneal window by means of a large incision just beneath the right ovarian hilus, followed by coagulation of the edges of the window

(figure 1). The goal was to induce angiogenesis and neovascularisation in this area. Both ovaries looked atrophic. Nevertheless, a small corpus luteum was visible on the left ovary. We recorded a reduction in LH and FSH (figure 2) and concentrations then returned to those at castration.

We did a second laparoscopy 7 days after creation of the peritoneal window. A biopsy sample of 4–5 mm in size was taken from each of the atrophic ovaries to check for the presence or absence of primordial follicles.

We thawed the cryogenic vials at room temperature (between 21°C and 23°C) for 2 min and immersed them in a water bath at 37°C for another 2 min. We immediately transferred ovarian tissue from the vials to tissue culture dishes (Becton Dickinson, NY, USA) in Leibovitz medium and we subsequently washed the tissue three times with fresh medium to remove cryoprotectant before further processing.

Thawed ovarian cortical tissue was placed in sterile medium and immediately transferred to the operating theatre. We pushed the large strip and 35 small cubes of frozen-thawed ovarian tissue into the furrow created by the peritoneal window very close to the ovarian

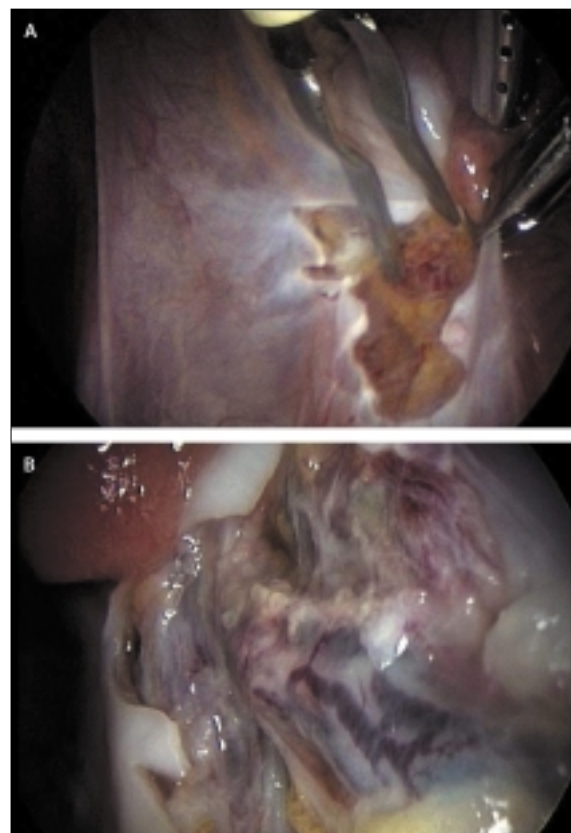


Figure 1: Site of reimplantation

(A) During the first laparoscopy (7 days before transplantation), a peritoneal window was created and the edges of the window were coagulated. (B) 7 days later (day of reimplantation), an extensive vascular network was clearly visible in this space.

vessels and fimbria on the right side. No suture was used. An extensive neovascular network was clearly visible in this space (figure 1). We used vital fluorescent staining (Molecular Probes, Leiden, Netherlands) to confirm survival of primordial follicles after freeze-thawing.¹⁵

After long discussion with the oncologists and the patient, a third laparoscopy was proposed. At least three reasons were given to justify the procedure: (1) to check viability of the orthotopic grafts, 4 months after transplantation, by laparoscopic visualisation and histological analysis; (2) to check for absence of any cellular growth anomalies (peritoneal fluid, histology), the cortical strip and cubes having been biopsied before chemotherapy; and (3) to reimplant the remaining ovarian cortical cubes, by request of the patient, who was now aged 32 years. Indeed, if pregnancy had not ensued from the reimplanted tissue, she would have considered oocyte donation. A validated technique will probably not need so many surgical procedures in the future.

Role of the funding source

The sponsor of the study had no role in study design, data collection, data analysis, data interpretation, or writing of the report. The corresponding author had full access to all the data in the study and had final responsibility for the decision to submit for publication.

Results

Vital fluorescent staining confirmed survival of all primordial follicles after freeze thawing. By contrast, no primordial follicles were noted in serial sections of the four biopsy samples taken from either of the atrophic ovaries at the second or third laparoscopy. Follicular density was between 4 and 5 follicles per μL .

After the first transplantation, LH and FSH concentrations fell again (figure 2). Vaginal echography then confirmed the presence of a corpus luteum on the left ovary. LH and FSH concentrations again returned to castrated levels and vaginal echography failed to show any ovarian activity until 5 months after reimplantation.

The day before the third laparoscopy, ultrasonography clearly showed the presence of a follicle outside the ovaries, which both appeared atrophic. The atrophic ovaries looked like dense echogenic structures measuring about 2 cm long and 0.75–1 cm wide. The follicular structure could be seen clearly separated (0.5–1 cm) from the right ovary. At this laparoscopy, the ovaries were still atrophic without any signs of ovarian activity. At the site of reimplantation, the follicular structure seen at vaginal echography was visible and subsequently biopsied (figure 3). The biopsy sample showed granulosa cells were present, as proved by presence of cells immunohistochemically expressing inhibin A (figure 3).¹⁶ The grafted cubes could also be seen, and one of them was biopsied for assessment of

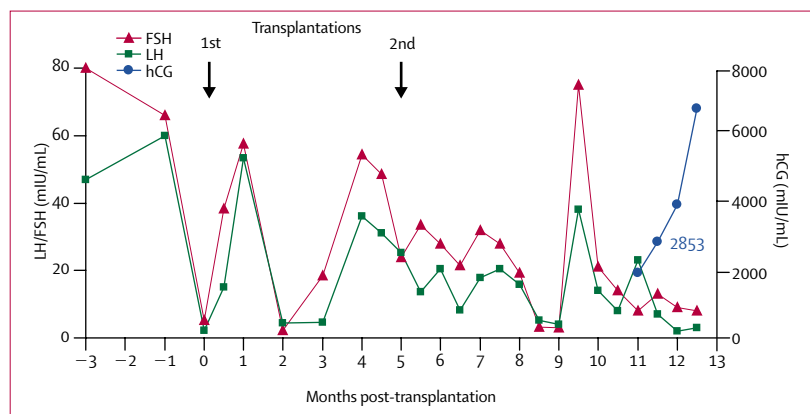


Figure 2: Sequential serum concentrations of FSH and LH

hCG=human chorionic gonadotrophin. 5 months after reimplantation, restoration of ovarian endocrine function was shown by assessment of hormone concentrations. 11 months after reimplantation, an ongoing intrauterine pregnancy was diagnosed.

primordial follicle survival (figure 4). Follicular viability was proven by presence of two primordial follicles, which were coloured by vital fluorescent staining (figure 4). The remaining 32 cubes were then reimplanted at the site of the ovarian graft biopsy on the right side. At that time, a slight reduction in LH and FSH was seen, concomitantly with follicular development in the grafted area.

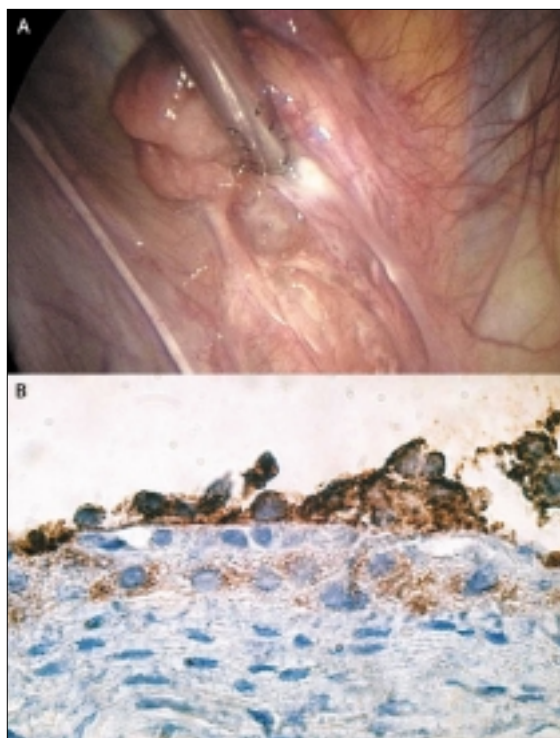


Figure 3: Follicle from the grafted tissue

(A) Laparoscopic view of the follicular structure at the site of the large strip implantation. (B) Histology of the follicular wall showing presence of cells expressing inhibin A (brown). Original magnification $\times 100$.

From 5 to 9 months after reimplantation, ultrasonography revealed development of a follicle followed by corpus luteum formation with every menstrual cycle at the site of reimplantation; this corresponded with an oestradiol concentration of more than 100 pg/mL and a progesterone level of 12–37 ng/mL. Amounts of LH and FSH were lower than those observed before reimplantation. This change led to restoration of consecutive menstrual bleeding every month.

At 9.5 months, FSH concentrations rose to 78.7 mIU/mL and returned to normal values 7 days later. 3 weeks later, a follicle of 2.6 cm in size had developed on the right side, clearly outside the right ovary (figure 5). Both native ovaries were well visualised and obviously atrophic. 18 days after ovulation, calculated by basal body temperature, the concentration of human chorionic gonadotrophin was 2853 mIU/ml. We should stress that conception arose spontaneously since neither ovarian stimulation nor IVF had been done. Because we do not yet know whether transplanted tissue can sustain ovarian steroid hormone support during pregnancy, we initiated progesterone treatment (administered vaginally at a dose of 600 mg per day).

Vaginal ultrasonography at 8 weeks confirmed a viable intrauterine pregnancy (figure 5). Triple test evaluation and ultrasonography did not reveal any anomalies. The pregnancy resulted in the livebirth of a healthy girl, weighing 3.72 kg, with an Apgar score of 9 at 1 min, 9 at 5 min, and 9 at 10 min.

Discussion

We report a livebirth after successful orthotopic transplantation of cryopreserved ovarian tissue in a woman with stage IVab Hodgkin's lymphoma.

Unfortunately, in most female cancer patients, aggressive chemotherapy and radiotherapy leads to ovarian failure. Restoration of ovarian function after

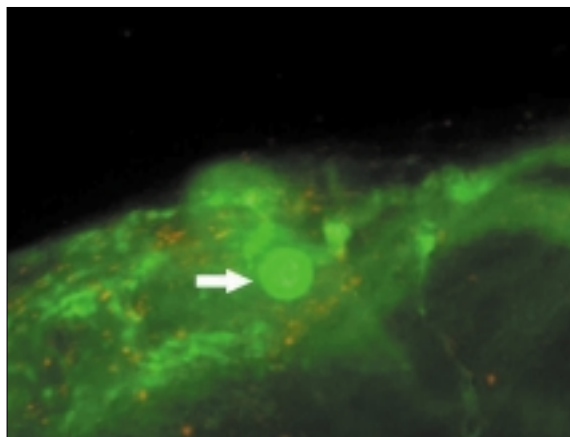


Figure 4: Biopsy sample of a frozen-thawed cube, 5 months after reimplantation

Vital fluorescent staining by calcein-AM and ethidium homodimer 1 indicated viable primordial follicles, coloured in green (arrow). Original magnification $\times 20$.

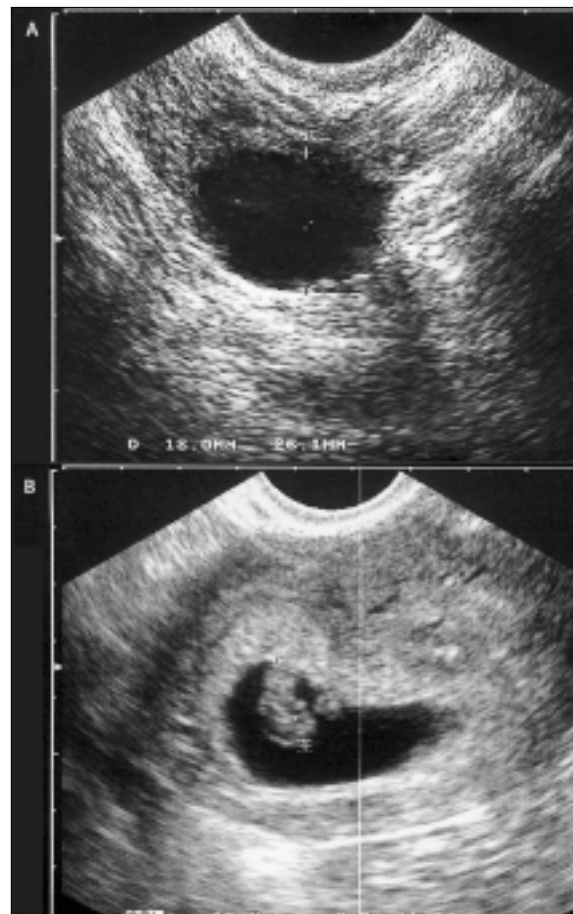

Figure 5: Vaginal ultrasonography

(A) Vaginal echography showing a follicle of 18 \times 26 mm in size at the site of ovarian cortex transplantation. (B) Ongoing intrauterine pregnancy (8 weeks). Crown-rump length=15 mm, cardiac activity +.

chemotherapy or radiotherapy has two main goals: to improve quality of life and restore reproductive function. For patients who need immediate chemotherapy, ovarian tissue cryopreservation, undertaken before cancer treatment starts, could be a means of preserving fertility without delaying initiation of chemotherapy. However, one major concern surrounding use of ovarian cortical strips for orthotopic autotransplantation is the potential risk that the frozen-thawed ovarian cortex might harbour malignant cells, which could induce a recurrence of disease after reimplantation. Shaw and colleagues¹⁷ reported that ovarian grafts from AKR mice could transfer lymphoma to recipient animals. Nevertheless, findings of other studies have suggested that ovarian tissue transplantation in Hodgkin's disease is safe.^{18–20}

In our study, histological assessment of ovarian cortex before and after reimplantation found no evidence of disease. But, confirmation of the absence of malignant cells by light microscopy might not be sufficient, especially in other types of cancer (eg, haematogenous or systemic neoplasms).²¹ Screening methods to detect

minimal residual disease must be developed to eliminate risk of cancer cell transmission with reimplantation.⁵

To date, ovarian tissue has been successfully cryopreserved and transplanted in rodents, sheep, and marmoset monkeys.^{11,22,23} A successful fertilisation and pregnancy after egg collection from fresh transplanted ovarian tissue in a primate has been described:¹⁴ the grafted tissue functioned without any surgical connection to major blood vessels. Experimental studies have indicated that the fall in number of primordial follicles in grafted tissue is due to hypoxia and the delay before reimplanted cortical tissue becomes revascularised. The loss of primordial follicles in cryopreserved ovarian tissue after transplantation is estimated to be 50–65% in some studies.^{7,10,11} In one trial, in which ovarian cortex was grafted onto the uterine horn and under the skin, the loss was more than 90%.²⁴

Oktaç and colleagues¹³ suggested that oocyte quality might be compromised by transplantation to a heterotopic site. Indeed, they only obtained a four-cell embryo from 20 oocytes retrieved from tissue transplanted under the skin of the abdomen. Temperature and pressure changes in the subcutaneous space could damage the oocytes.

We have previously shown that peritoneal tissue is superior to subcutaneous tissue as a site of transplantation, with loss of fewer follicles in peritoneal tissue.¹⁰ This model also showed effective revascularisation in the peritoneal layer and led us to propose orthotopic transplantation.

In the case we describe, vaginal echography and laparoscopy revealed a follicular structure 5 months after frozen-thawed ovarian tissue transplantation. The grafted tissue was biopsied, and histological analysis and fluorescent probe staining revealed the presence of viable primordial follicles and a follicular structure with inhibin A-marked cells. Follicles at an early growth stage need more than 85 days to reach the antral stage.²⁵ Primordial follicles obviously need even more. The appearance of the first follicle in the grafted tissue 5 months after reimplantation is totally consistent with the expected time course. This time interval seen in our study between implantation of cortical tissue and the first oestradiol peak (5 months) is also consistent with data obtained from sheep and human beings.^{11,12}

From 5 to 9 months after reimplantation, concentrations of FSH, 17 β -oestradiol, and progesterone showed the occurrence of ovulatory cycles. At 9.5 months, the patient had a sudden and temporary surge in FSH (79 mIU/mL). 3 weeks later, the patient ovulated and, from this ovulation, became pregnant. We cannot explain this sudden and temporary surge in FSH. Possibly, it was associated with a decline in inhibin secretion, as suggested in the sheep model,^{26,27} or with slower follicular growth from a poor follicular reserve in the graft. Indeed, because of the loss of primordial follicles in the transplant, the follicular density was low

but, in any case, the total amount of cortical tissue transplanted is fairly unimportant. After transplantation, the patient would have been regarded as a poor responder because, of the 500–1000 primordial follicles that would have been transplanted, more than 50% would have been lost owing to hypoxia.¹⁰ The FSH surge seen here probably served to favour follicle recruitment.

Several lines of evidence lend support to our assertion that the origin of the pregnancy was the autotransplanted cryopreserved tissue. First, the patient had, in total, three ovulatory cycles over a period of more than 2 years. All originated from the left native ovary, which was proved by laparoscopy, echography, or both. Second, the native right ovary never showed any ovarian activity at all (no follicles, no corpus luteum). Third, even if we cannot absolutely exclude the presence of isolated follicles in the atrophic ovary, their density must be very low, since serial sections of four large biopsy samples of atrophic ovaries failed to detect any follicles. Fourth, laparoscopy showed, by direct visualisation, the development of a follicle from the grafted tissue 5 months after reimplantation. Fifth, on histological examination, the biopsy samples indicated not only survival of primordial follicles in the grafted tissue but also maturation of a follicle (granulosa cells marked by inhibin A). Sixth, after follicular development was shown by laparoscopy and histology, the patient had regular menstrual bleeding. The concentration of progesterone was systematically more than 10 ng/mL in the mid-luteal phase, calculated on the basis of basal body temperature. During every ovulatory cycle (from 5 to 9 months), vaginal echography showed a corpus luteum on the grafted tissue outside the right atrophic ovary, which had shown no ovarian activity for almost 3 years. Finally, vaginal echography revealed the presence of a preovulatory follicle (figure 4) at the reimplantation site during the cycle leading to the pregnancy, but no follicles were seen on either of the native ovaries. This argument is a crucial one.

Our findings open new perspectives for young cancer patients facing premature ovarian failure. Ovarian tissue cryopreservation should be an option offered to all young women diagnosed with cancer, in conjunction with other existing options for fertility preservation, such as immature oocyte retrieval, in-vitro maturation of oocytes, oocyte vitrification, or embryo cryopreservation.

Contributors

J Donnez initiated the study, did surgery, and wrote the report. M M Dolmans did histological analysis and obtained data. D Demylle was responsible for cryopreservation of ovarian tissue. P Jadoul, C Pirard, and J Squifflet helped with surgical procedures and clinical follow-up. B Martínez-Madrid did histological analysis. A Van Langendonck supervised the laboratory components of the study.

Conflict of interest statement

We declare that we have no conflict of interest.

Acknowledgments

This work was supported by a grant from the Fonds National de la Recherche Scientifique de Belgique (grant FNRS-Télévie) no 7.4520.02.

References

- 1 Donnez J, Godin PA, Qu J, Nisolle M. Gonadal cryopreservation in the young patient with gynaecological malignancy. *Current Opin Obstet Gynecol* 2000; **12**: 1–9.
- 2 Larsen EC, Schmiegelow K, Rechnitzer C, Loft A, Müller J, Anderson AN. Radiotherapy at a young age reduces uterine volume of childhood cancer survivors. *Acta Obstet Gynecol Scand* 2004; **83**: 96–102.
- 3 Blatt J. Pregnancy outcome in long-term survivors of childhood cancer. *Med Pediatr Oncol* 1999; **33**: 29–33.
- 4 Donnez J, Bassil S. Indications for cryopreservation of ovarian tissue. *Hum Reprod* 1998; **4**: 248–59.
- 5 Rao GD, Chian RC, Son WS, Gilbert L, Tan SL. Fertility preservation in women undergoing cancer treatment. *Lancet* 2004; **363**: 1829–30.
- 6 Gosden RG, Baird DT, Wade JC, Webb R. Restoration of fertility to oophorectomised sheep by ovarian autografts stored at –196°C. *Hum Reprod* 1994; **9**: 597–603.
- 7 Meirou D, Fasouliotis SJ, Nugent D, Schenker JG, Gosden RG, Rutherford AJ. Laparoscopic technique for obtaining ovarian cortical biopsy specimens for fertility conservation in patients with cancer. *Fertil Steril* 1999; **71**: 948–51.
- 8 Oktay K, Karlikaya G. Ovarian function after transplantation of frozen, banked autologous ovarian tissue. *N Engl J Med* 2000; **342**: 1919.
- 9 Oktay K, Economos K, Kan M, Rucinski J, Veecks L, Rosenwaks Z. Endocrine function and oocyte retrieval after autologous transplantation of ovarian cortical strips to the forearm. *JAMA* 2001; **286**: 1490–93.
- 10 Nisolle M, Casanas-Roux F, Qu J, Motta P, Donnez J. Histologic and ultrastructural evaluation of fresh and frozen-thawed human ovarian xenografts in nude mice. *Fertil Steril* 2000; **74**: 122–29.
- 11 Baird DT, Webb R, Campbell BK, Harkness LM, Gosden RG. Long-term ovarian function in sheep after ovariectomy and transplantation of autografts stored at –196°C. *Endocrinology* 1999; **140**: 462–71.
- 12 Radford JA, Lieberman BA, Brison D, et al. Orthotopic reimplantation of cryopreserved ovarian cortical strips after high-dose chemotherapy for Hodgkin's lymphoma. *Lancet* 2001; **357**: 1172–75.
- 13 Oktay K, Buyuk E, Veeck L, et al. Embryo development after heterotopic transplantation of cryopreserved ovarian tissue. *Lancet* 2004; **363**: 837–40. Published online March 9, 2004 (<http://image.thelancet.com/extras/04art2215web.pdf>).
- 14 Lee DM, Yeoman RR, Battaglia DE, et al. Live birth after ovarian tissue transplant. *Nature* 2004; **428**: 137–38.
- 15 Cortvrindt R, Smitz J. Fluorescent probes allow rapid and precise recording of follicle density and staging in human ovarian cortical biopsies. *Fertil Steril* 2001; **75**: 588–93.
- 16 Galant C, Berlière M, Dubois D, et al. Focal expression and final activity of matrix metalloproteinases may explain irregular dysfunctional endometrial bleeding. *Am J Pathol* 2004; **165**: 83–94.
- 17 Shaw JM, Bowles J, Koopman P, Wood EC, Trounson AO. Fresh and cryopreserved ovarian tissue samples from donors with lymphoma transmit the cancer to graft recipients. *Hum Reprod* 1996; **11**: 1668–73.
- 18 Kim SS, Radford JA, Harris M, et al. Ovarian tissue harvested from lymphoma patients to preserve fertility may be safe for autotransplantation. *Hum Reprod* 2001; **16**: 2056–60.
- 19 Kim SS, Battaglia DE, Soules MR. The future of human ovarian cryopreservation and transplantation: fertility and beyond. *Fertil Steril* 2001; **75**: 1049–56.
- 20 Kim SS. Ovarian tissue banking for cancer patients: to do or not to do? *Hum Reprod* 2003; **18**: 1759–61.
- 21 Meirou D, Yehuda DB, Prus D, et al. Ovarian tissue banking in patients with Hodgkin's disease: is it safe? *Fertil Steril* 1998; **69**: 996–98.
- 22 Candy CJ, Wood MJ, Whittingham DG. Restoration of a normal reproductive lifespan after grafting of cryopreserved mouse ovaries. *Hum Reprod* 2000; **15**: 1300–04.
- 23 Candy CJ, Wood MJ, Whittingham DG. Follicular development in cryopreserved marmoset ovarian tissue after transplantation. *Hum Reprod* 1995; **10**: 2334–38.
- 24 Aubard Y, Piver P, Cognié Y, Fermeaux V, Poulin N, Driancourt MA. Orthotopic and heterotopic autografts of frozen-thawed ovarian cortex in sheep. *Hum Reprod* 1999; **14**: 2149–54.
- 25 Gougeon A. Dynamics of follicular growth in the human: a model from preliminary results. *Hum Reprod* 1986; **1**: 81–87.
- 26 Callejo J, Salvador C, Miralles A, Vilaseca S, Laila JM, Balasch J. Long-term ovarian function evaluation after autografting by implantation with fresh and frozen-thawed human ovarian tissue. *J Clin Endocrinol Metab* 2001; **86**: 4489–94.
- 27 Campbell BK, Telfer EE, Webb R, Baird DT. Ovarian autografts in sheep as a model for studying folliculogenesis. *Mol Cell Endocrinol* 2000; **163**: 131–39.